



# Acute clouding of a trifocal intraocular lens during implantation: A case report

Kemal Ozulken<sup>a</sup>, Sabite Emine Gokce<sup>b</sup>, Kemal Tekin<sup>c,\*</sup>

<sup>a</sup> TOBB ETU School of Medicine, Department of Ophthalmology, Ankara, Turkey

<sup>b</sup> Dr. Abdurrahman Yurtaslan Training and Research Hospital, Department of Ophthalmology, Ankara, Turkey

<sup>c</sup> Ulucanlar Eye Training and Research Hospital, Department of Ophthalmology, Ankara, Turkey

## ARTICLE INFO

### Keywords:

Cataract  
Clouding  
Intraocular lens  
Implantation

## ABSTRACT

**Purpose:** In this paper, we present a case of acute clouding of a trifocal intraocular lens (IOL) that resolved spontaneously by the day after surgery.

**Observations:** A 68-year-old woman with a nuclear cataract in the right eye was scheduled for cataract surgery with +21.00 diopter trifocal IOL (AT LISA tri 839MP, Carl Zeiss Meditec AG, Germany) implantation. Phacoemulsification was uneventful until the implantation of the IOL. Although the IOL was initially transparent, we observed acute clouding of the IOL optic immediately upon implantation into the eye, and the IOL remained cloudy at the end of the surgery. On the day after surgery, we observed that the clouding was completely resolved.

**Conclusions and Importance:** We think that the sudden temperature change of the IOL upon implantation into the anterior chamber may have caused acute clouding. If a similar situation is encountered, clinicians should avoid explantation or replacement of the Zeiss AT LISA trifocal IOL, as the clouding resolves spontaneously.

## 1. Introduction

Acrylic intraocular lenses (IOLs) are manufactured from a wide variety of copolymers with varying refractive indexes, water contents, glass-transition temperatures, and surface properties. Hydrophobic acrylic IOLs have very low water contents (<1%) compared with hydrophilic IOLs, whose water contents vary from 18% to 38%.<sup>1</sup> Post-operative delayed opacification of hydrophilic acrylic IOLs leading to eventual explantation has been reported previously.<sup>2</sup> Acute clouding of acrylic hydrophilic IOLs is a less-encountered intraoperative phenomenon that has been reported primarily in monofocal hydrophilic acrylic IOLs.<sup>3</sup>

We present a case of acute clouding of a trifocal IOL that resolved spontaneously by the day after surgery.

### 1.1. Case presentation

A 68-year-old woman with a nuclear cataract in the right eye was scheduled for cataract surgery with +21.00 diopter trifocal IOL (AT LISA tri 839MP, Carl Zeiss Meditec AG, Germany) implantation. Phacoemulsification was carried out under topical anesthesia and was

uneventful until IOL implantation. Although the IOL was initially transparent, we observed acute clouding of the IOL optic immediately upon implantation into the eye (Fig. 1, Video). The IOL remained cloudy at the end of the surgery (Fig. 2, Video). However, we decided to leave the IOL in place. On the day after surgery, we observed that the clouding was completely resolved (Fig. 3).

## 2. Discussion

Due to the ever-increasing postoperative vision expectations of patients, premium IOLs are often implanted in modern cataract surgery. Recently, trifocal IOLs have gained great interest due to their intermediate vision advantage over multifocal IOLs. We report a patient who developed acute clouding of a trifocal IOL following intraocular implantation. Acute clouding of acrylic hydrophilic IOLs has been reported primarily in monofocal hydrophilic acrylic IOLs.<sup>3</sup> Unlike the hydrophilic acrylic lenses previously reported to become cloudy in vivo, the AT LISA trifocal IOL has hydrophobic surface properties. The anticipated cause of acute intraoperative clouding of acrylic hydrophilic IOLs is the external temperature fluctuation that occurs when the IOL is transferred to the operating room from an outside facility shortly before surgery.<sup>3,4</sup> The

\* Corresponding author.

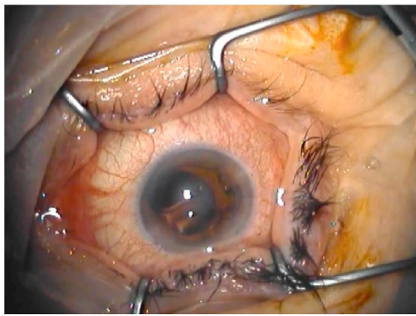
E-mail address: [kemal\\_htepe@hotmail.com](mailto:kemal_htepe@hotmail.com) (K. Tekin).

<https://doi.org/10.1016/j.ajoc.2022.101258>

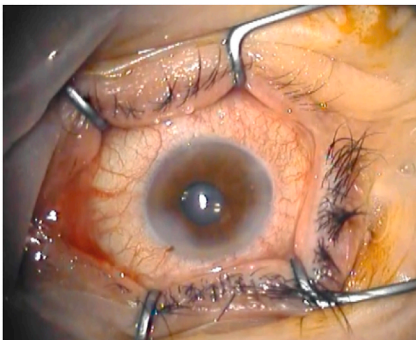
Received 29 September 2019; Received in revised form 1 August 2021; Accepted 13 January 2022

Available online 20 January 2022

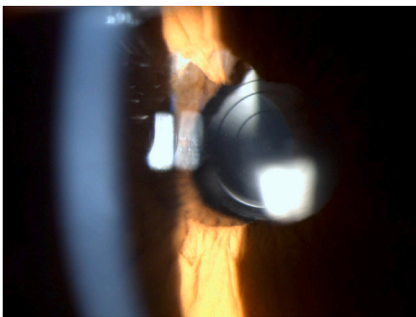
2451-9936/© 2022 The Authors. Published by Elsevier Inc. This is an open access article under the CC BY license (<http://creativecommons.org/licenses/by/4.0/>).



**Fig. 1.** Acute clouding of the optic of the trifocal IOL was observed as soon as it was implanted into the eye.



**Fig. 2.** Trifocal IOL remains cloudy at the end of the surgery.



**Fig. 3.** Postoperative first day of the cataract surgery, the IOL was observed as completely clear.

subsequent abrupt change of the IOL temperature upon implantation into the anterior chamber may facilitate acute clouding. The Zeiss AT LISA manufacturer's manual indicates that the IOL temperature should be kept within a specified range (2–45 °C) before implantation. Clinicians should be aware of this phenomenon, especially during winter, and IOLs should be allowed to acclimate to the operating room temperature before implantation. When hydrophilic acrylic (25%) IOLs with hydrophilic surface properties are stored in a cool location, short-term opacification can occur immediately after implantation. This reaction is related to the significant change of temperature (cold to hot) when the lens is taken from a cool location, such as the trunk of a car in winter, to the warmth of the patient's eye within a short period of time. The phenomenon behind this opacification is a temporary reorganization of water molecules, a totally reversible reaction that does not change the chemical, mechanical or geometric properties of the polymer. After the temperature of the lens is equalized with the ambient temperature, this opacity disappears. Tyagi et al.<sup>3</sup> reported a case in which acute clouding of a monofocal acrylic hydrophilic IOL resolved after 3 hours. Similar to our case, Liu et al.<sup>4</sup> reported a case in which two different AT LISA

trifocal lenses implanted into the same eye experienced the same clouding phenomenon; however, they eventually explanted both lenses. In the same case report, the surgeons replaced the second trifocal IOL with a monofocal hydrophobic acrylic IOL (ZCBOO, Tecnis, J&J) after obtaining patient consent. IOL explantation is usually performed by partially or completely dissecting the IOL in the anterior chamber after prolapsing it out of the capsular bag, followed by removing the pieces through the corneal wound. While the rate is low in the hands of experienced surgeons, extensive surgical manipulations in the anterior chamber still bear the risk of intraoperative complications that may lead to unsatisfactory final visual outcomes. Although the clouding phenomenon was previously encountered in the same lens type, our case differs in that we decided to leave the IOL in place and found that the clouding completely disappeared by the day after surgery. Therefore, if intraoperative acute clouding is observed, we suggest avoiding explantation or replacement of the Zeiss AT LISA trifocal lens to prevent reobtaining patient consent, changing the surgical plan, and increasing the related surgical risks.

### 3. Conclusion

In conclusion, despite its hydrophobic surface properties, the Zeiss AT LISA trifocal IOL is still prone to the intraoperative acute clouding phenomenon mainly encountered in hydrophilic acrylic IOLs. We anticipate that acute intraoperative clouding of the trifocal IOL (Zeiss AT LISA) is caused by external temperature fluctuation. Therefore, we suggest that the IOL temperature should be kept within the manufacturer-specified range before implantation, especially in winter. This may avoid acute clouding caused by an abrupt temperature change during implantation. If clouding is encountered, clinicians should avoid explantation or replacement of the Zeiss AT LISA trifocal IOL, as the clouding resolves spontaneously. However, to better clarify this clouding phenomenon, *in vitro* clouding testing of the lens implanted at different temperature extremes would be appropriate.

### Funding

This research received no specific grant from any funding agency in the public, commercial, or not-for-profit sectors.

### Patients consent

It was taken. In the form, the patient has given his consent for his/ images and other clinical information to be reported in the journal.

### Acknowledgements

The authors report no conflicts of interest and have no proprietary interest in any of the materials mentioned in this article.

All authors attest that they meet the current ICMJE criteria for Authorship.

### Appendix A. Supplementary data

Supplementary data to this article can be found online at <https://doi.org/10.1016/j.ajoc.2022.101258>.

### References

1. Srinivasan S. Intraocular lens opacification: what have we learned so far. *J Cataract Refract Surg.* 2018;44:1301–1302.
2. Neuhann IM, Werner L, Izak AM, et al. Late postoperative opacification of a hydrophilic acrylic (hydrogel) intraocular lens: a clinicopathological analysis of 106 explants. *Ophthalmology.* 2004;111:2094–2101.
3. Tyagi P, Shah N, Jabir M. Intraoperative clouding of a posterior chamber intraocular lens. *Int Ophthalmol.* 2011;31:483–484.
4. Liu Q, Zhang S, Wang X, Cao W, Jia Y. Acute clouding of trifocal lens during implantation: a case report. *BMC Ophthalmol.* 2017;17:242.